

Original article

Imaging appearances of central nervous system infections associated with HIV infection

¹Dr. Narendrakumar M Shah , ²Dr Vaishali D M

¹Associate professor, Department of Radiodiagnosis ,SDM Medical college, Dharwad

²Consultant radiologist, NMR imaging centre, Hubli

Name of the Institute/college: SDM medical college

Corresponding author: Dr. Narendrakumar M Shah

Abstract:

Patients with AIDS develop a variety of central nervous system lesions that can result from HIV itself or from secondary opportunistic infections. Imaging plays an important role in the diagnosis of these lesions and in assessing the response to treatment. Knowledge of the spectrum of imaging findings of these infectious diseases is important in the evaluation of HIV infected patients. In this article we describe the imaging findings of few of the central nervous system infections in HIV patients.

Introduction:

HIV is a retrovirus that infects the cells of immune system and disrupts their function. CNS manifestations in patients with HIV infection can arise from HIV infection itself or from opportunistic infections, neoplasms or drug related complications. The opportunistic infections associated with HIV include progressive multifocal encephalopathy, toxoplasmosis, cytomegalovirus infections, cryptococcosis, tuberculosis and pyogenic infections. Patients is most vulnerable to CNS infections when the CD4 counts fall below 200cells/cumm.

Study design:

The MR images of head in patients with HIV infection were retrospectively reviewed. The MR images of 20 patients with evidence of CNS infection were selected. The imaging appearance, distribution pattern, enhancement pattern were studied.

Discussion:

HIV encephalopathy: AIDS – dementia complex/ HIV –associated dementia complex is a secondary subcortical dementia resulting from direct infection of the CNS with HIV. ¹ The clinical findings include inattention, indifference and psychomotor slowing.² CT findings include cerebral atrophy inappropriate for patients's age and symmetric abnormal low attenuation in periventricular and deep white matter. MR findings include include cerebral atrophy and patchy or confluent T2 hyperintensity in periventricular and deep white matter. Contrast enhancement and mass effect are typically absent (figure 1). ³ MRS demonstrates decreased NAA and elevated choline and NAA peaks. ⁴ DTI helps in early detection of white matter lesions.

HIV vasculitis: HIV-related vasculitis including a primary HIV vasculitis has been described in pathologic studies of AIDS patients. The lenticulostriate vessels are the most vulnerable. Inflammation begins in the adventitia and involves the vasa vasorum, which leads to

ischemia of the arterial wall, resulting in the destruction of elastic lamina and subintimal fibrosis. This panarteritis could then lead to stenosis and/or aneurismal dilatation. Resultant infarcts or hemorrhages can occur (figure 2).⁵

Progressive multifocal leucoencephalopathy (PML):

PML is a fulminating opportunistic infection of the brain caused by JC papovavirus. JC virus targets the oligodendrocytes which are responsible for myelin production and thus causes myelin breakdown and white matter destruction.⁶ The clinical features include cognitive impairment, altered mental status, and personality changes. The CT findings include asymmetric focal zones of low attenuation in the periventricular and subcortical white matter. On MRI the lesions are multifocal and hyperintense on T2 weighted images. The lesions start in the start in the subcortical white matter and then spread to the deep white matter. Subcortical U fiber involvement is typically seen.^{2,3} Faint peripheral contrast enhancement may be seen.⁷ MR spectroscopy demonstrates a reduction in NAA, presence of lactate, and increased amounts of choline and lipids.²

Toxoplasmosis: Toxoplasmosis is the most frequent and treatable opportunistic CNS infection in patients with HIV and is caused by the parasite *Toxoplasma gondii*.⁷ The corticomedullary junction, basal ganglia, thalamus and the brainstem are commonly involved.⁸ Patients may present with symptoms from mass effect, focal neurologic deficits, seizures, or cranial nerve palsies. Toxoplasmic lesions begin as foci of encephalitis that progress rapidly to parenchymal abscesses with central necrosis and surrounding inflammation.

CT findings include multiple iso- or hypodense lesions, enhancing in a ring or nodular pattern with perifocal vasogenic edema and mass effect.⁷ At MR imaging, toxoplasmosis lesions are typically

hypo- to isointense on T2 weighted images and are surrounded by high-signal-intensity vasogenic edema (figure 3). Hemorrhage may be seen occasionally, a finding that can help differentiate toxoplasmosis from lymphoma, which typically does not hemorrhage before treatment.⁹

One of the close differential diagnosis for toxoplasmosis is lymphoma. If the lesions remain stable or increase in size 10–14 days after beginning of a specific treatment, immediate brain biopsy is indicated to exclude lymphoma.³ Increased uptake on Thallium 201 SPECT and FDG PET is seen in lymphomas, whereas no uptake is found in toxoplasmosis.¹⁰ On MRS, lactate and lipids are elevated, with reduction or absence of all normal brain metabolites in toxoplasmosis lesions, whereas a prominent increase in choline could be observed in lymphoma.¹¹

Tuberculosis: The CNS manifestations of tuberculosis include meningitis, communication hydrocephalus, tuberculomas, tubercular abscess and cerebral ischemia/infarction.² Tubercular meningitis usually involves the basal cisterns and is usually associated with communicating hydrocephalus secondary to obstruction of the basal cisterns. Tuberculomas may be solitary or multiple and are usually supratentorial. On imaging they are hypointense on T2 weighted images (figure 4). Non caseating tuberculomas show nodular enhancement and caseating tuberculomas show ring like enhancement pattern. Tubercular abscesses have a T2 hyperintense centre. On MR spectroscopy, tubercular abscesses show a lipid lactate peak and no amino acid peak. Cerebral infarction results from vasospasm and thrombosis of the small perforating arteries as they course through the pass through the thick basilar exudates.¹²

Pyogenic infections: Pyogenic intracranial infections are relatively uncommon in the AIDS

population. Staphylococcus and Streptococcus are the most common causative organisms. The imaging findings seen in AIDS patients are

identical to those seen in immunocompetent patients (figure 5).

Figure 1:

Axial FLAIR MR images of the brain in a HIV patient showing cerebral atrophy and symmetric periventricular white matter hyperintensity.

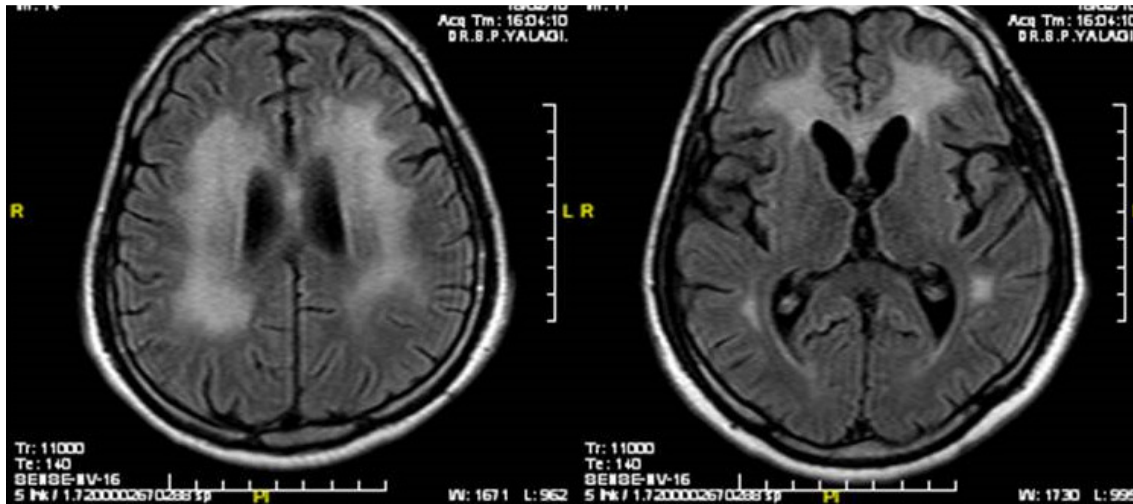


Figure 2:

Axial contrast enhanced and diffusion weighted MR images of brain in a HIV patient with HIV meningitis and vasculitis showing leptomenigeal enhancement and lacunar acute infarcts in bilateral frontoparietal white matter/basal ganglia

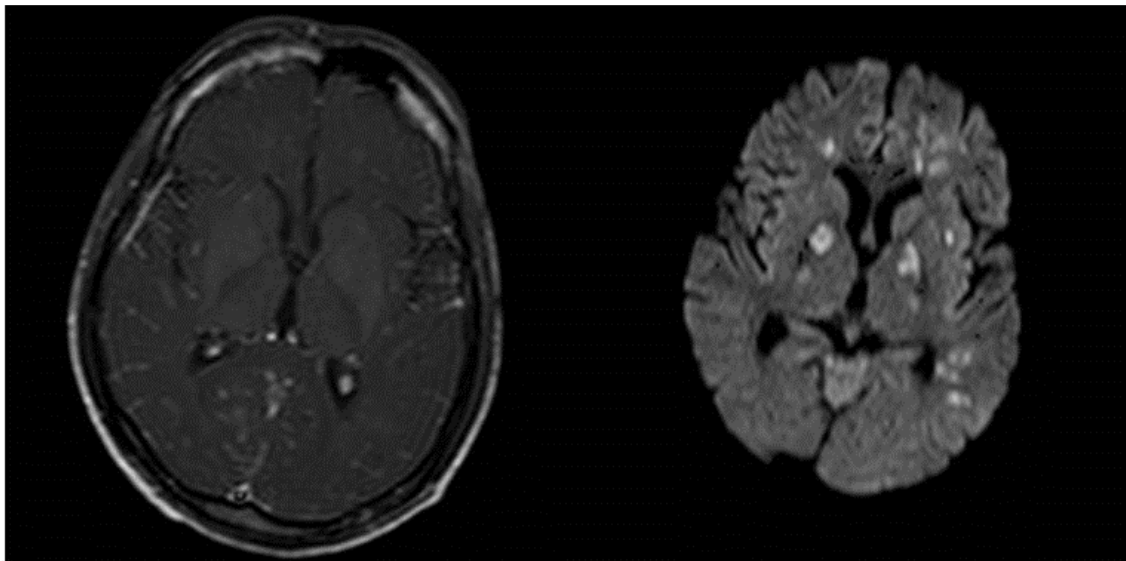


Figure 3:

Axial T1 weighted and T2 weighted MR images of brain in a HIV patient with toxoplasmosis showing T1 hyperintense signals on treatment.

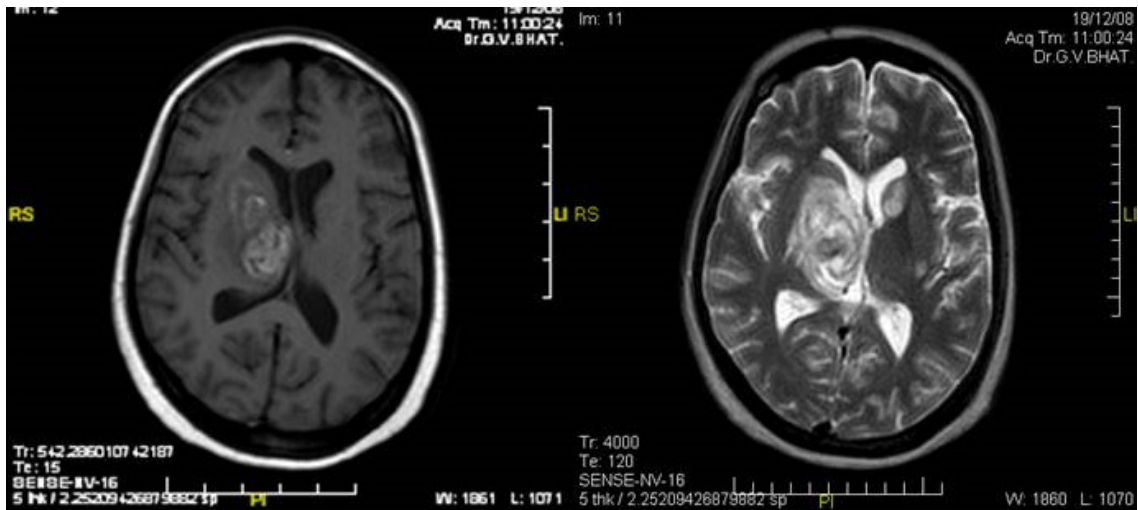


Figure 4:

Axial T2 weighted MR images in two different HIV infected patients with tuberculosis infection showing tuberculomas that are hypointense on T2 weighted images with perilesional edema.

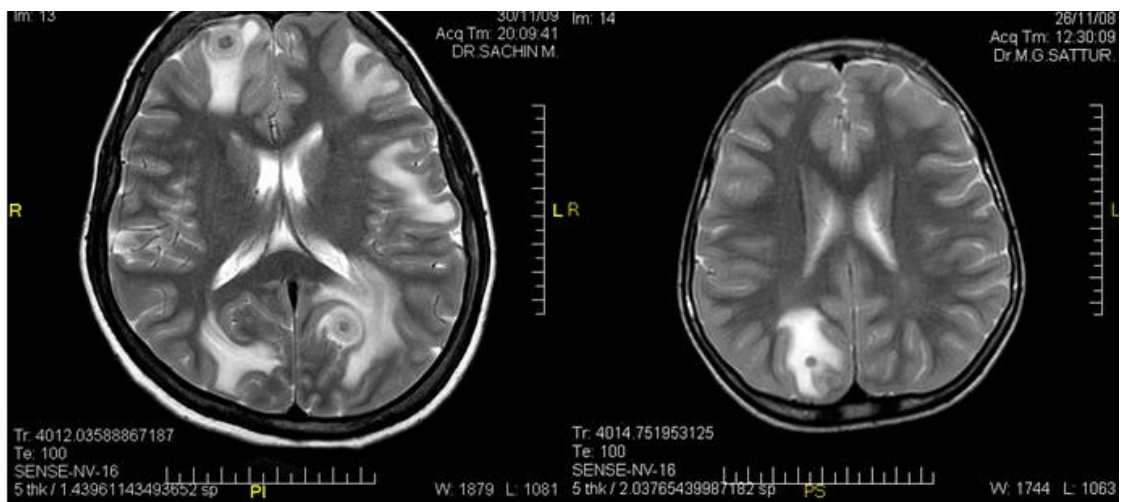
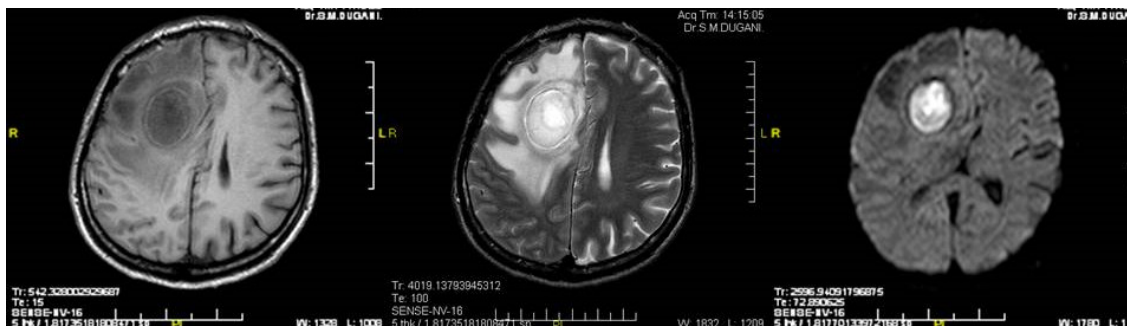


Figure 5:

Axial T1 weighted, T2 weighted and diffusion weighted MR images in a patient with HIV infection and right frontal lobe pyogenic cerebral abscess showing a lesion that is hypointense on T1 and hyperintense on T2 with restricted diffusion and perilesional edema.



Conclusion:

A variety of infections can affect the central nervous system in patients with HIV infection. Diagnostic imaging studies serve as an adjunct to clinical and laboratory studies in the management of AIDS. Knowledge of the imaging findings of these infections helps in diagnosis.

References

1. Takeuchi M, Nobukuni K, Takata H, et al. Rapidly progressed acquired immunodeficiency syndrome dementia complex as an initial manifestation. *Intern Med* 2005; 44:757–760
2. Smith AB, Smirniotopoulos JG, Rushing EJ. Central nervous system infections associated with human immunodeficiency virus infection: Radiologic-pathologic correlation. *Radiographics* 2008 28;7, 2033-2058
3. Thurnher MM, Thurnher SA, Schindler E. CNS involvement in AIDS: spectrum of CT and MR findings. *Eur Radiol* 1997; 7:1091– 1097
4. Laubenberger J, Haussinger D, Bayer S, et al. HIV related metabolic abnormalities in the brain: depiction with proton MR spectroscopy with short echo times. *Radiology* 1996;199(3):805–810
5. O'Charoen P, Hesselink JR, Healy JF. Cerebral aneurysmal arteriopathy in an adult patient with acquired immunodeficiency syndrome. *AJNR Am J Neuroradiol* 2007; 28:938–939
6. Post MJ, Yiannoutsos C, Simpson D, et al. Progressive multifocal leukoencephalopathy in AIDS: are there any MR findings useful to patient management and predictive of patient survival? AIDS Clinical Trials Group, 243 Team. *AJNR Am J Neuroradiol* 1999; 20:1896–190
7. Roulet E. Opportunistic infections of the central nervous system during HIV-1 infection (emphasis on cytomegalovirus disease). *J Neurol* 1999; 246:237–243
8. Offiah CE, Turnbull IW. The imaging appearances of intracranial CNS infections in adult HIV and AIDS patients. *Clin Radiol* 2006; 61:393–401
9. Trenkwalder P, Trenkwalder C, Feiden W, Vogl TJ, Einhaupl KM, Lydtin H. Toxoplasmosis with early intracerebral hemorrhage in a patient with the acquired immunodeficiency syndrome. *Neurology* 1992;42(2):436–438

10. Hoffman JM, Waskin HA, Schifter T, et al. FDG-PET in differentiating lymphoma from nonmalignant central nervous system lesions in patients with AIDS. *J Nucl Med* 1993; 34:567–575
11. Centers for Disease Control and Prevention (CDC). Trends in HIV/AIDS diagnoses among men who have sex with men--33 States, 2001-2006. *MMWR Morb Mortal Wkly Rep* 2008; 57:681–686
12. Sheller JR, Des Prez RM. CNS tuberculosis. *Neurol Clin* 1986;4(1):143–158.